

Demhasaj v Fluid Trans Corp.

2021 NY Slip Op 33991(U)

October 25, 2021

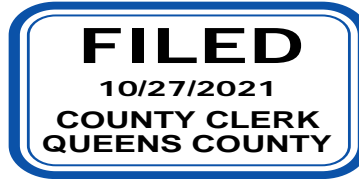
Supreme Court, Queens County

Docket Number: Index No. 710249/2019

Judge: Ulysses B. Leverett

Cases posted with a "30000" identifier, i.e., 2013 NY Slip Op 30001(U), are republished from various New York State and local government sources, including the New York State Unified Court System's eCourts Service.

This opinion is uncorrected and not selected for official publication.



SUPREME COURT OF THE STATE OF NEW YORK
COUNTY OF QUEENS

-----X
HAJDIN DEMHASAJ

Plaintiffs,

-against-

FLUID TRANS CORP. and GEORGE A. DANKWA,
Defendant.

-----X
Present: **HONORABLE ULYSSES B. LEVERET:**

Notice of Motion-Affirmation-Exhibits.....
Affirmation In Opposition-Exhibits.....
Reply Affirmation.....

Index No.: 710249/2019

Motion Seq. No. 001

Decision and Order

Papers Numbered

EF-12-28
EF-32-38
EF-39

Upon the foregoing papers, it is ordered that defendants Fluid Trans Corp. and George A. Dankwa’s motion for an order pursuant to CPLR § 3212 granting defendant summary judgment and dismissing the plaintiff’s complaint on the ground that plaintiff Hajdin Demhasaj did not sustain a serious injury as defined by Insurance Law 5102 (d) is denied.

This action was brought to recover damages for serious personal injuries allegedly sustained by plaintiff Hajdin Demhasaj as a result of being hit as a pedestrian by a taxi motor vehicle owned by defendant Fluid Trans Corp. and operated by defendant George A. Dankwa on March 23, 2019 at or near the intersection of 5th Avenue and 34th Street, County of New York, State of New York. Plaintiff states that he was struck on the left side by defendants’ vehicle and propelled into the air and thrown several feet landing on the roadway some distance away from the impact point. Plaintiff states that as a result of the impact, he sustained serious injuries to his neck, back, and left knee.

Insurance Law § 5102(d) defines a “serious injury” as “ a personal injury which results in death; dismemberment; significant disfigurement; a fracture, loss of a fetus, permanent loss of use of a body organ, member, function or system; permanent consequential limitation of use of a body organ or member; significant limitation of use of a body function or system; or a medically determined injury or impairment of a non-permanent nature which prevents the injured person from performing substantially all of the material acts, which constitute such person’s usual and customary daily activities for not less than 90 days during the 180 days immediately following the occurrence of the injury or impairment.”

In support of the motion, defendants assert that plaintiff did not sustain a serious injury as defined in Insurance Law § 5102 (d). Defendants submitted a sworn report dated February 12, 2021 from Dr. Salvatore Corso, an orthopedic surgeon who performed an independent orthopedic evaluation on plaintiff on October 13, 2020 and reviewed plaintiff’s medical records. Plaintiff’s cervical spine range of motion measurements taken with a goniometer revealed flexion to 50 degrees (50 degrees normal), extension to 60 degrees (60 degrees normal), right rotation 80

degrees (normal 80 degrees), left rotation 75 degrees (normal 80 degrees) right/left lateral flexion 45 degrees (normal 45 degrees). No spasm noted and no atrophy of the cervical musculature. Cervical spine demonstrated right/left paracervical tenderness.

The lumbar spine range of motion revealed flexion to 60 degrees (60 degrees normal), extension to 25 degrees (25 degrees normal), right/left rotation 25 degrees (normal 25 degrees). The lumbosacral spine demonstrates tenderness over the right left paralumbar. No spasm noted.

Bilateral shoulders range of motion examination revealed forward flexion 180 degrees (normal 180 degrees), extension 40 degrees (normal 40 degrees), abduction to 180 degrees (normal 180 degrees), adduction to 30 degrees (normal 30 degrees), external rotation to 90 degrees (normal 90 degrees), internal rotation 80 degrees (normal 80 degrees). No erythema and crepitus was found and there was no instability.

Examination of the right knee revealed medial and lateral joint line tenderness with no effusion. Flexion of 150 degrees (150 degrees normal), extension of 0 degrees (0 degrees normal). No signs of instability and no atrophy. Examination of the left knee revealed flexion of 130 degrees (140 degrees normal), extension of 0 degrees (0 degrees normal). There is no effusion and there is tenderness at the patella. Examination of the bilateral ankles/feet revealed no swelling and no effusion and normal ranges of motion.

Dr. Corso states that plaintiff's injuries to the cervical spine, lumbar spine, shoulders, left/right knee and ankles are all resolved, and that plaintiff did not sustain a significant or permanent injury as a result of the subject accident. Dr. Corso asserts that there are no objective clinical findings indicative of a present disability, and functional impairment, which prevents plaintiff from engaging in his usual daily activities including work, school, and hobbies.

Defendant submitted an April 2, 2020 report by Dr. Darren Fitzpatrick, a board certified radiologist who performed an independent radiology review of plaintiff 4/30/2019 lumbar spine MRI and states that the MRI revealed L2 pars interarticularis defect with associated slight anterolisthesis of L2 on L3 and accelerated degenerative disc disease at L2-L3. Dr Fitzpatrick concludes that plaintiff has sustained no traumatic injury and that the findings are associated with degenerative disease.

Dr. Fitzpatrick's findings of plaintiff's 6/17/2020 left knee MRI revealed a normal marrow signal, medial and lateral menisci intact, no fluid collection or effusion. Dr. Fitzpatrick concludes that plaintiff sustained no traumatic injury to his left knee.

Where a defendant has made a showing sufficient for entitlement to summary judgment, the burden shifts to the plaintiff to raise an issue of material fact as to whether plaintiff has sustained a serious injury. See *Alvarez v Prospect Hospital*, 68 NY 2d 320 (1986).

Plaintiff in opposition states that defendant has not demonstrated that plaintiff did not sustain a serious injury as defined by Insurance Law § 5102 (d) and that plaintiff has raised

triable issues of fact that she did indeed sustain a serious injury. Plaintiff submitted a June 14, 2021 sworn report from Dr. Thomas Nuguyen, a chiropractor who last examined plaintiff on 4/6/2021 and reviewed plaintiff's objective medical diagnostic tests. Dr. Nuguyen's range of motion testing of plaintiff's cervical and thoracic spine with a dual Inclinometer revealed cervical spine flexion restricted to 35 degrees (45 degrees normal), extension to 45 degrees (55 degrees normal), right rotation 60 degrees (normal 70 degrees), left rotation 55 degrees (normal 70 degrees), right lateral flexion 40 degrees (normal 45 degrees), left lateral flexion 35 degrees (normal 45 degrees). Thoracic-lumbar spine flexion restricted to 60 degrees (90 degrees normal), extension to 20 degrees (30 degrees normal), right rotation 15 degrees (normal 20 degrees), left rotation 15 degrees (normal 20 degrees), right lateral flexion 25 degrees (normal 30 degrees), left lateral flexion 20 degrees (normal 30 degrees).

Dr. Nuguyen states that following his examination and review of plaintiff's MRI's and other diagnostic and electrodiagnostic testing, it is his expert chiropractic opinion that plaintiff has sustained permanent and significant injuries as a result of the subject motor vehicle accident and that plaintiff is permanently impaired. He states that plaintiff's disc pathology as diagnosed via MRI are not degenerative or pre-existing in nature, are permanent as well as plaintiff's limited range of motion and that plaintiff has a partial permanent disability.

Plaintiff submitted a June 16, 2021 sworn report from Dr. Jinghui Xie, a board certified anesthesiologist who last examined plaintiff on 5/15/2021 for complaints of pain to plaintiff's lower back, neck and knees. Dr. Xie's findings included C2-3 disc bulge indenting the thecal sac, cervical derangement, radiculopathy, lumbar derangement, myofascial pain, lumbar facet syndrome and knee sprain. Dr. Xie states that in his expert medical opinion, with a reasonable degree of medical certainty that the injuries were causally related to the subject accident, that the injuries are of a permanent nature and inhibits plaintiff's ability to carry out his normal activities of daily living.

Plaintiff submitted a June 30, 2021 sworn report from Dr. Kenneth McCulloch, who last examined plaintiff on 5/26/2021 and reviewed plaintiff's left knee MRIs. Plaintiff's range of motion examination on plaintiff's left knee using a goniometer revealed 0-120 degrees (0-150 degrees normal). There was medial joint line tenderness to palpation with equivocal McMurrays's and also retropatellar tenderness to palpation. Dr. McCulloch states that his diagnosis was left knee traumatic focal interstitial tear involving the distal anterior cruciate ligament fibers, small suprapatellar joint effusion, stress marrow edema in the medial patella and posterior midline tibial plateau, left knee derangement and contusion. Dr. McCulloch asserts that it is his expert medical opinion that the patient's injuries were causally related to the subject accident which would inhibit the plaintiff's ability to carry out his normal activities of daily living and that the injuries are permanent in nature.

Plaintiff submitted a June 29, 2019 sworn report from Dr. Siddharth Prakash, a radiologist who read plaintiff's cervical spine MRI, and found straightening of the normal cervical lordosis, no compression fracture, multilevel loss of disc hydration was noted. Dr. Prakash's 4/30/2019 reading of plaintiff's lumbar spine MRI revealed normal lumbar lordosis, mild lumbar levoscoliosis is present, disc spaces are hydrated., grade 1 etrolisthesis and left paracentral broad based disc herniation superimposed on a disc bulge at L2-L3 indenting the


thecal sac, lateral recesses and foramina, abutting the bilateral exiting L2 nerve roots. Dr. Prakash's reading of plaintiff's 6/17/2019 left knee MRI revealed inter alia focal interstitial tear involving the distal anterior cruciate ligament fibers, small suprapatellar joint effusion and stress marrow edema in the medial patellar and posterior midline tibial plateau.

It is well established that the proponent of summary judgment motion must make a prima facie showing of entitlement to judgment as a matter of law, tendering sufficient evidence to demonstrate the absence of any material issue of fact. See *Zuckerman v City of New York*, 49 NY 2d 557 (1980). Here, the affirmed medical reports of the parties' doctors directly contradict each other. Where parties offer conflicting medical evidence on the existence of a serious injury, the existence of such injury is a matter for a jury's determination. See *Cracchiolo v Omerza*, 87 AD 3d 674 (2011).

The Court finds triable issues of fact as to the existence of serious injury. Accordingly, defendants Fluid Trans Corp. and George A. Dankwa's motion for an order pursuant to CPLR § 3212 granting defendant summary judgment and dismissing the plaintiff's complaint on the ground that plaintiff Hajdin Demhasaj did not sustain a serious injury as defined by Insurance Law 5102 (d) is denied.

This is the decision and order of this Court.

Dated: October 25, 2021


Ulysses B. Leverett, JSC

